

La technique « POEM » myotomie œsophagienne par endoscopie flexible

Per-Oral Endoscopic Myotomy (POEM) for Esophageal Achalasia

H Inoue

Mots clés

- ◆ POEM
- ◆ Achalasia
- ◆ Heller-Dor
- ◆ Achalasia sigmoïdienne

Résumé

Objectifs. La myotomie œsophagienne per-orale par endoscopie flexible (POEM) est une alternative non-invasive au traitement chirurgical de l'achalasia. La technique de ce procédé a été mise au point après une expérimentation animale préalable ayant permis de confirmer la bonne faisabilité d'une myotomie œsophagienne par abord sous-muqueux.

Méthode. Le procédé POEM a été officiellement approuvé par un Comité d'Évaluation et un consentement explicite obtenu de tous les patients avant l'intervention. Les interventions ont toutes été l'objet d'un enregistrement dans la base prospective de données de notre Université. Les indications opératoires ont concerné toutes les formes d'achalasia, à part les formes terminales justiciables d'une œsophagectomie. 420 patients ont été traités selon cette technique depuis 2008.

Sous anesthésie générale avec insufflation de CO₂ est inséré un endoscope /0° avec coiffe distale transparente (Olympus MH-588). Une lame à extrémité triangulaire (Olympus KD-640L) est utilisée pour la dissection du plan sous-muqueux et des fibres musculaires circulaires. Après injection sous-muqueuse de 10 ml de sérum physiologique, une incision longitudinale de 2 cm est pratiquée 13 cm en amont de la jonction œsogastrique. L'utilisation d'une coagulation par pulvérisation facilite la dissection de ce plan jusqu'à l'estomac, 3 cm au-dessous de la jonction. La section des faisceaux musculaires circulaires est pratiquée, dans une zone située sur l'œsophage à 2h, commençant à 2 cm de l'incision muqueuse et se prolongeant jusqu'à 2 cm au-dessous de la jonction œsogastrique. La muqueuse est fermée par des clips hémostatiques.

Résultats. Chez 43 patients, l'achalasia avait été à l'origine d'un œsophage de type sigmoïde. La longueur moyenne du tunnel pratiqué a été de 15 cm avec un maximum de 26, et sa largeur a intéressé approximativement le tiers de la circonférence de l'œsophage. Un pneumopéritoine s'est produit dans 6 % des cas et a justifié une ponction abdominale. Chez l'un de nos opérés, est survenue une péritonite convenablement contrôlée par les antibiotiques et, chez un autre, un pneumothorax a nécessité un drainage. L'amélioration considérable du score/symptômes a été notée dans tous les cas, avec toutefois la nécessité pour un petit nombre de patients d'une dilatation unique par sonde à ballonnet. Un reflux acide symptomatique a été observé dans 23,5 % des opérés, avec traitement par les IPP pour 4,8 %.

Conclusion. Le procédé POEM par endoscopie œsophagienne flexible est un procédé nouveau, peu invasif, du traitement de l'achalasia. Il peut être appliqué aux achalasia de tous stades de sévérité. Ses résultats à court et moyen terme sont excellents.

Keywords

- ◆ POEM
- ◆ Achalasia
- ◆ Heller-Dor
- ◆ Sigmoid achalasia

Abstract

Objective. Per-oral endoscopic myotomy (POEM) aims to represent a less invasive alternative to the surgical of achalasia. It was developed after experimental animal studies demonstrated the feasibility of submucosal myotomy.

Methods. The POEM procedure was approved by the institutional review board and informed consent was obtained from all patients. Procedures were registered in a prospective university database. Indications include all forms of achalasia except the terminal stage requiring esophagectomy. Since 2008, 420 consecutive patients were treated using this approach.

Under general anesthesia with CO₂ insufflation, a 0° endoscope with a transparent distal cap (MH-588, Olympus) is inserted. A triangle tip knife (KD-640L, Olympus) is used to dissect the submucosal layer and to divide the circular muscle bundles. A 2 cm longitudinal incision is made on the esophageal mucosa after a submucosal injection of 10 ml saline 13 cm proximal to the gastroesophageal (GE) junction. Spray coagulation mode allows the dissection of the submucosal space down to the stomach, 3 cm below the GE junction. Circular muscle bundles are divided in a 2 o'clock position starting 2 cm from the mucosal incision to 2 cm below the GE junction. The mucosal opening is closed by hemostatic clips.

Results. 43 of the patients had sigmoid achalasia. The mean length of the tunnel was 15 cm with a maximum of 26 cm and its width was approximately 1/3 of the esophageal circumference. Pneumoperitoneum occurred in

Correspondance :

Pr Haruhiro INOUE, MD - Digestive Disease Center

Showa University Northern Yokohama Hospital, Chigasaki-Chuo 35-1, Tsuzuki-ku, Yokohama 224-8503 Japan

E-mail : haruinoue777@gmail.com - Home page : achalasia-poem.net

6%, sometimes requiring needle puncture of the abdomen. One patient had a localized peritonitis controlled by antibiotics and another required a chest tube for a pneumothorax. Symptom score improved dramatically in all cases but a few patients required single balloon dilatation. Symptomatic acid reflux was observed in 23.5% and 4.8% of the patients were treated by proton pump inhibitors.
Conclusion. POEM is a novel less invasive treatment of esophageal achalasia with no skin incision. POEM can be applied to any grade achalasia. Short - to middle-term results are excellent.

The concept of natural orifice transluminal endoscopic surgery (NOTES) (1-3) has inspired endoscopists and endoscopic surgeons to create and establish novel less invasive treatment even for various gastrointestinal diseases. Esophageal achalasia is one of the considerable target of NOTES. So far, treatments including Botox injection and balloon dilation have been commonly performed as first-line endoscopic treatments for achalasia (4,5). If those are ineffective, laparoscopic myotomy are generally indicated as the next step of treatment (6).

Per-oral endoscopic myotomy (POEM) has been developed as a further less invasive endoscopic treatment intending permanent cure from esophageal achalasia (7). In the literature a concept of endoscopic myotomy was firstly reported around 3 decades ago (8), but direct incision method through mucosal layer described in that literature was not considered as a safe and reliable procedure. Pasricha PJ et al recently reported possibility of submucosal myotomy using porcine model (9). Sumiyama K et al also reported technical usefulness of submucosal tunnelling in porcine model. Based on these experimental data, novel method of endoscopic myotomy was developed and established by present authors (10). In this *syllabus* current techniques of POEM are described.

IRB approval and Informed consent

The POEM procedure received approval from the institutional review board (IRB) of Showa University Northern Yokohama Hospital (approval number 0805-02, issued on August 15, 2008). Written informed consent was obtained from all patients. All patients who underwent POEM were registered in the University Hospital Medical Information Network Japan (UMIN) database.

Indication of POEM

All achalasia patients can be treated by POEM. In our early series the indication of POEM was limited to non-sigmoid type, but patient feedbacks to the POEM procedure were better than expected. Then it is opened to all grade of achalasia. More recently indication of POEM was further extended to the cases of failed laparo- or thoracoscopic surgical myotomy. Now we have no exception of application of POEM. Only exclusion is terminal achalasia which is generally treated by esophagectomy.

Equipment used for POEM

A forward-viewing endoscope of outer diameter 9.8 mm, which is designed for routine upper gastrointestinal screening with water jet, is used with a transparent distal cap attachment (MH-588, Olympus or short ST hood, Fuji). This distal attached cap is of great importance for keeping a better endoscopic vision even in submucosal space. With the oblique orifice, the endoscope may be smoothly inserted into the submucosal layer. All equipment including endoscope itself is sterilized using ethylene oxide gas.

A triangle-tip knife (KD-640L, Olympus) was used to dissect the submucosal layer and also to divide circular muscle bundles. The maximum diameter for insertion portion of KD-640L is 2.6 mm. For electro-surgical energy generator a VIO 300D

electrogenerator (ERBE, Tübingen, Germany) is recommended to use. Generator mode of Spray coagulation in ERBE300D allows non-contact tissue dissection. It makes submucosal dissection to create tunnel much easier and faster with less bleeding.

A coagulating forceps (Coagrasper, FD-411QR; Olympus) is used to close larger vessels, if it exists, prior to dissection and for hemostasis.

Carbon dioxide gas is used for insufflation during the procedure with a CO₂ insufflator (UCR; Olympus). CO₂ insufflator with a regular insufflating tube (MAJ-1742; Olympus) offers controlled gas feeding of 1.2 liter/minute during procedure. Endoscopic CO₂ insufflation is beneficial for reducing the risk of both mediastinal emphysema and air embolization. At that time it should be confirmed that ignition light of air feeding button should be kept off. Otherwise, air will be also supplied together with CO₂ insufflation. CO₂ insufflation is crucial factor to achieve safe POEM. Special attention should be paid in order to avoid air insufflation. This is totally same concept of CO₂ insufflation during laparoscopic and thoracoscopic surgery.

For final closure of the mucosal entry site, hemostatic clips (EZ-CLIP, HX-110QR; DF Olympus) are applied. Using hemostatic clips mucosal entry can be closed tightly. Tight closure of mucosal incision avoids leakage of esophageal content into *mediastinum*.

Procedure of POEM

Step 1. Intratracheal intubation and CO₂ insufflation

The procedures are done with the patient under general anesthesia. Please note severe emphysema may occur if POEM would be done only with conscious sedation without intratracheal intubation. Positive pressure ventilation is definitely helpful in reducing the risk of mediastinal emphysema. During POEM under general anesthesia, pneumoperitoneum (not *pneumomediastinum*) occurred in 6% (18 among 300 cases). In order to prevent from becoming abdominal compartment syndrome, upper abdominal wall is prepared to be exposed and then checked periodically during POEM procedure. When abdominal wall is excessively extended, puncture of abdominal cavity using injection needle is effective to reduce abdominal pressure by leaking excessive CO₂ gas in the peritoneal cavity.

Step 2. Creation of a submucosal tunnel

Mucosal entry

Submucosal injection of about 10 ml saline with 0.3% indigo carmine is given before opening the mucosal surface (figure 1). The position of the entry usually lies in the anterior wall. Two cm longitudinal incision in two o'clock direction is on the line directly connecting to lesser curve of the stomach. On this line submucosal tunnel can be created straightly from distal esophagus to cardiac without injury to sling muscle. Submucosal injection was generally done at the level of the mid esophagus, approximately 13 cm proximal to the GE junction. It is a level just below carina (approximately 29 cm from

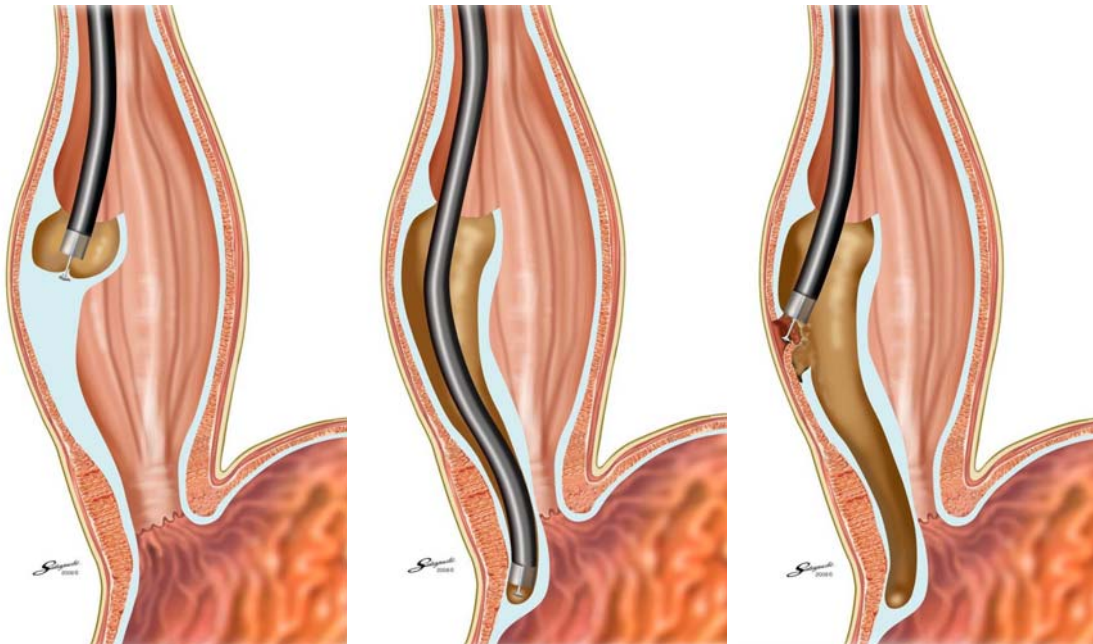


Figure 1. Opening the mucosal surface.

Figure 2. Dissecting plane.

Figure 3. Dissection of the circular muscle bundle.

patient's incisa). Abnormal contractions of esophageal body usually located at the middle and lower third of the esophagus. Estimated length of tunnel becomes 16 cm (29 cm-45 cm). When we start myotomy at the level of just below carina, almost all abnormal contraction has been dissected. A 2 cm longitudinal mucosal incision was made on the mucosal surface to create a mucosal entry to the submucosal space (Endocut I, effect 2, cut 1, duration 6).

If the patient happens to have abnormal contraction of esophageal middle third much longer myotomy is expected. Longer myotomy may effectively control chest pain caused by spasm of hypertrophied circular muscle.

Submucosal tunnel

The tunnel is made downwards by using a technique similar to ESD, passing over the EGJ and enter the proximal stomach about 3 cm. Using triangle-tip knife (TT knife) submucosal tissue is dissected by non-touching technique with spray coagulation mode, 50W, effect 2 on ERBE 300D. Dissection by spray coagulation looks similar to APC, but this setting supplies more cutting energy. Dissecting plane is definitely just beneath muscle layer surface (figure 2). Please note never to dissect close to mucosal layer, because mucosal layer is an only barrier between esophageal lumen and *mediastinum* after completion of myotomy. Mucosal damage or mucosal defect potentially may cause serious complication.

The length of the submucosal tunnel is usually approximately 15 cm, but should depend on the individual abnormality. If a patient complains chest pain because of abnormal contraction of esophageal body, much longer submucosal tunnelling is required. Our longest tunnel was 26 cm. During submucosal dissection, repeated submucosal injection makes submucosal tissue dissection easier whenever the demarcation between submucosal layer and muscular layer becomes unclear. The width of the tunnel is about 1/3 of the circumferential of the tubular esophagus. Palisade vessel in the submucosal layer is helpful in identifying the EGJ. Once tip of endoscope is getting into the cardia, submucosal space will be opened widely. The distal margin of the tunnel can be easily checked with a retroflexed view from the cardia by the blue submucosal tattoo. Larger vessels in the submucosa are coagulated using the hemostatic forceps in soft coagulation mode (80W, effect 5).

Identification of GEJ

Another interesting issue with the POEM technique concerns identification of the GEJ in the submucosal space. As clear markers for identifying the GEJ junction, the following indicators should be checked. The first indicator is the insertion depth of the endoscope from the incisors. The position of the GEJ junction in the lumen of the esophagus itself was therefore recorded accurately in advance before we inserted the endoscope into the submucosal tunnel. Insertion depth of the endoscope in the submucosal space is almost the same as the accurate position of the endoscope in the true lumen. The submucosal tunnel created ends at least 3 cm long enough distal to the estimated GEJ. The second indicator is a marked increase of resistance when the endoscope approaches the GEJ, followed by a prompt easing when the endoscope passes through the narrow GEJ and enters the stomach submucosal area. The working space in the submucosal tunnel also becomes gradually narrower when the endoscope approaches closely to the LES. At the LES segment, movement of the endoscope is obviously limited with high resistance. Once the endoscope has passed through narrow segment, the submucosal space promptly widens adjacent to the stomach. The third indicator is endoscopic visual identification of palisade vessels in the submucosal layer. Palisade vessels are located at the distal end of the esophagus. These vessels were endoscopically identified in all cases. Finally, the fourth indicator is a change of vasculature in the submucosal layer. In the esophageal submucosal space few vessels are observed in the submucosal layer, but when the stomach is reached the submucosal vasculature suddenly becomes rich like a spider nest.

Step 3. Endoscopic myotomy

Dissection of sphincter muscle

Dissection of the circular muscle bundle was begun at 2 cm distal to the mucosal entry, more than 10 cm above the GEJ (figure 3). The sharp tip of the triangle-tip knife was used to first catch a couple of circular muscle bundles and then to lift them up toward the esophageal lumen. The captured circular muscle bundle was cut by spray coagulation current (50W, effect 2). At the beginning of myotomy nobody knows how thick inner circular muscle is. Only transverse muscle bundle should be caught and then cut by electrocautery. By several

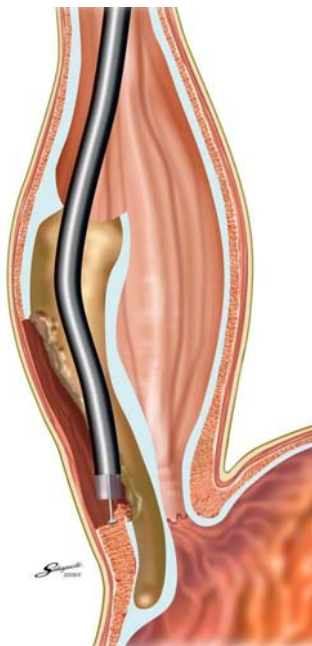

Figure 4. Muscle layer cutting-continued for at least 2 cm distal to the GEJ.

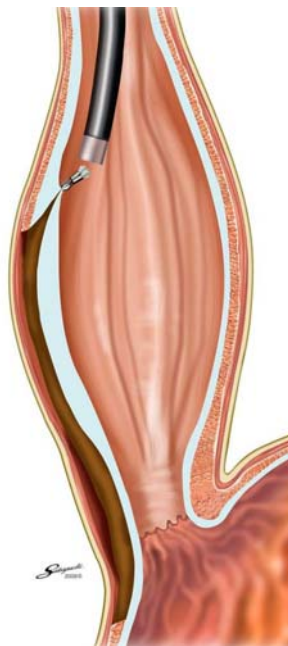


Figure 5. The mucosal entry site closed with clips.

cuts of transverse muscle bundles a plain of longitudinal muscle is identified at the bottom of myotomy site. This intramuscular space is the best layer to be continuously dissected with maintaining longitudinal muscle layer intact. In any case outer longitudinal muscle layer is thin enough like a sheet of paper. It is regarded to have less special function of muscle contraction. By trying to keep outer longitudinal layer intact, operator can potentially reduce the risk of injury to mediastinal structure surrounding esophagus.

Division of the sphincter muscle was continued from the proximal side towards the stomach until the endoscope passed through the narrow segment of the LES. Longitudinal muscle layer should be carefully preserved during the dissection procedure. Longitudinal muscle layer is actually thin enough like a sheet of paper. It is easy to tear, and then *mediastinum* tissue is often exposed to submucosal tunnel. Even though this happens, no negative clinical effects occur. By trying to preserve a longitudinal muscle sheet intact, unnecessary injury to adjacent structure of the esophagus can be potentially avoided.

How to avoid symptomatic GERD

Anterior myotomy in the two o'clock direction in the supine position seems most appropriate, as this leads to the lesser gastric curvature. In contrast, the angle of His is located at in the eight o'clock direction. Anterior myotomy potentially avoids damage to the sling muscle, and eventually His angle keeps its original angulation.

The related topic of gastroesophageal reflux disease (GERD) should be discussed. In surgical myotomy an antireflux measure, such as a Dor procedure, is also carried out in order to avoid postoperative GERD, since adjacent structures surrounding the distal esophagus are inevitably dissected which may impair natural antireflux mechanisms. With POEM no antireflux procedure is carried out, since the endoscopist never touches surrounding structures. However, complete myotomy potentially may have a risk for post-therapeutic GERD.

When the tip of the endoscope reached the stomach region, the submucosal space suddenly became wider. Thickness of inner circular muscle layer is different in individual cases. Muscle layer cutting continued for at least 2 cm distal to the GEJ (figure 4). Complete division of the circular muscle bundle was confirmed by the endoscopic appearance. Any muscle

bundle which runs transversely should not be remained. Complete hemostasis is also achieved using coagulating forceps. After completion of the myotomy, smooth passage of an endoscope through the GEJ with minimal resistance was confirmed.

Another major advantage of POEM is to set myotomy length as long enough to be expected. More than 10 cm myotomy is generally put. Particularly the patient complains chest pain which may be caused by abnormal contraction of hypertrophied muscle in the esophageal body, longer myotomy is put. In our series longest myotomy was 24 cm.

Step 4. Closure of mucosal entry

Before close the mucosal entry, 80 mg gentamycin is injected into the submucosal tunnel. The mucosal entry site, usually 2-3 cm long, was closed with about 5-10 hemostatic clips (figure 5). Sometimes mucosal entry hole tore a little bit longer, but it has no negative effect. Successful closure of the mucosal entry was confirmed by the endoscopic appearance. At the end of the procedure, the endoscope was again inserted into the natural lumen down to the stomach, to confirm smooth passage through the GEJ.

Examinations before POEM

Endoscopy, contrast media swallow and manometric study with high resolution manometry is essential to make correct diagnosis for esophageal achalasia. CT scan is used not only to judge the degree of esophageal dilatation, but also to provide information on the anatomical features of adjacent structures.

Clinical results in more than 300 cases

First case was done in September 8, 2008. 420 consecutive cases including 43 sigmoid achalasia received POEM. In all cases symptom score recovered dramatically. In most of the patients chest pain was reduced or totally disappeared. No major complications including mediastinitis, mass bleeding and mucosal necrosis occurred, but some minor complications occurred. In this series, a long myotomy with long submucosal tunnelling was done in most of the patients, but none showed clinically manifest mediastinitis. This suggests that the tight closure of the mucosal entry site using the endoscopic clipping device securely avoids the development of severe mediastinitis. Even though minor *pneumomediastinum* was seen by CT scan just after POEM, it was related to no significant clinical symptoms. One patient had local peritonitis focussing at lesser *omentum*, and it was controlled conservatively by prolonged prescription of antibiotics. In one case chest tube was temporarily inserted to control pneumothorax. In this case air was insufflated during POEM procedure together with CO₂. The improved condition was maintained without any additional treatment. No patients received additional therapy for achalasia except a few cases who received only single balloon dilatation with 20-mm balloon. Symptomatic GERD was observed 25.3%. 4.8% cases among 335 cases received PPI. All symptomatic GERD cases were well responded to PPI prescription. Ten cases of failure to surgical procedure (9 laparoscopic myotomies and one thoracoscopic myotomy) were consecutively treated by POEM. Symptom score was also improved dramatically in those patients.

Conclusion

POEM is a novel less invasive treatment of esophageal achalasia with no skin incision. POEM can be applied to any grade achalasia. Short- to middle-term results are excellent

References

1. Kalloo AN, Singh VK, Jagannath SB et al. Flexible transgastric peritoneoscopy: a novel approach to diagnostic and therapeutic interventions. *Gastrointest Endosc* 2004;60:114-7.
2. Zorron R, Filgueiras M, Maggioni LC et al. NOTES. Transvaginal cholecystectomy: report of the first case. *Sur Innov* 2007;14:279-83.
3. Marescaux J, Dallemagne B, Perretta S et al. Surgery without scars: report of transluminal cholecystectomy in a human being. *Arch Surg* 2007;142:823-6.
4. Spiess AE, Kahrilas PJ. Treating achalasia: from whalebone to laparoscope. *JAMA* 1998;280:638.
5. Pehlivanov N, Pasricha PJ. Achalasia: botox, dilatation or laparoscopic surgery in 2006. *Neurogastroenterol Motil* 2006;18:799-804.
6. Woltman TA, Pellegrini CA, Oelschlager BK. Achalasia. *Surg Clin N Am* 2005;85:483-93.
7. Inoue H, Minami H, Satodate H et al. First clinical experience of submucosal endoscopic myotomy for esophageal achalasia with no skin incision. *Gastrointest Endosc* 2009;69:AB122.
8. Ortega JA, Madureri V, Perez I. Endoscopic myotomy in the treatment of achalasia. *Gastrointest Endosc* 1980;26:8-10.
9. Pasricha PJ, Hawari R, Ahmed I et al. Submucosal endoscopic esophageal myotomy: a novel experimental approach for the treatment of achalasia. *Endoscopy* 2007;39:761-4.
10. Inoue H, Minami H, KobayashY et al. Per-oral endoscopic myotomy (POEM) for esophageal achalasia. *Endoscopy* 2010;42:265-71.

Recommended articles

1. Swanstrom LL, Rieder E, Dunst CM. A stepwise approach and early clinical experience in peroral endoscopic myotomy for the treatment of achalasia and esophageal motility disorders. *J Am Col Surg* 2011;213:751-8.
2. Ponsky JL, Marks J, Pauli EM. How I do it: per-oral endoscopic myotomy (POEM). *J Gastrointest Surg* 2012;16:1251-5.
3. Eleftheriadis N, Inoue H et al. Training in peroral endoscopic myotomy (POEM) for esophageal achalasia. *Ther Clin Risk Manag* 2012;8:329-42.